


This article was downloaded by: [Anonymous Registration for mpptwo]

On: 9 November 2009

Access details: Access Details: [subscription number 780368323]

Publisher Informa Healthcare

Informa Ltd Registered in England and Wales Registered Number: 1072954 Registered office: Mortimer House, 37-41 Mortimer Street, London W1T 3JH, UK



Acta Orthopaedica

Publication details, including instructions for authors and subscription information:

<http://www.informaworld.com/smpp/title~content=t713400243>

Treatment of Trigger Fingers

Vagn Kolind-sørensen^a

^a Department of Hand Surgery, Orthopaedic Hospital, Copenhagen, Denmark

Online Publication Date: 01 January 1970

To cite this Article Kolind-sørensen, Vagn(1970)'Treatment of Trigger Fingers',Acta Orthopaedica,41:4,428 — 432

To link to this Article: DOI: 10.3109/17453677008991530

URL: <http://dx.doi.org/10.3109/17453677008991530>

PLEASE SCROLL DOWN FOR ARTICLE

Full terms and conditions of use: <http://www.informaworld.com/terms-and-conditions-of-access.pdf>

This article may be used for research, teaching and private study purposes. Any substantial or systematic reproduction, re-distribution, re-selling, loan or sub-licensing, systematic supply or distribution in any form to anyone is expressly forbidden.

The publisher does not give any warranty express or implied or make any representation that the contents will be complete or accurate or up to date. The accuracy of any instructions, formulae and drug doses should be independently verified with primary sources. The publisher shall not be liable for any loss, actions, claims, proceedings, demand or costs or damages whatsoever or howsoever caused arising directly or indirectly in connection with or arising out of the use of this material.

Department of Hand Surgery, Orthopaedic Hospital, Copenhagen, Denmark

TREATMENT OF TRIGGER FINGERS

VAGN KOLIND-SØRENSEN

Received 25.x.69

In most cases a trigger finger is due to a disproportion between a flexor tendon and its tendon sheath: the tendon is squeezed in too narrow a canal. The finger may be completely locked or the tendon, upon a sudden effort, may glide through the narrowing and the characteristic trigger phenomenon will arise.

On a level with the metacarpo-phalangeal joint, there is the opening of the fibrous tendon sheath. In trigger finger, it is thickened and tight at this site, whereas the tendon itself shows spindle-shaped thickening in a localized area (Bunnell 1964, Flynn 1966, Pulvertaft 1966). Microscopic examination of the thickened tendon sheath reveals degenerative changes and proliferation of fibrous tissue (Fahey & Bollinger 1954).

The aetiology is unknown. The disease affects predominantly young children and menopausal women. In a number of cases trauma must be assumed to be responsible (Sperling 1952). Simultaneous occurrence in monozygotic twins (Fahey & Bollinger 1954) indicates an inherited factor. Trigger finger also commonly co-exists with rheumatic changes of the hand and may be the earliest sign of rheumatoid arthritis (Pulvertaft 1966).

The first sign is usually the trigger phenomenon. As a rule, it does not give rise to discomfort at once, but gradually it causes pain which may become quite severe.

In some cases locking occurs eventually, often in a flexed position, and this is the type most often found in children.

Operation has been recommended as an effective form of treatment (Bunnell 1964, Fahey & Bollinger 1954, Fogh-Andersen 1947). Through a small skin incision over the metacarpo-phalangeal joint the tendon sheath is exposed. A small window is cut into its proximal thickened part so that the tendon can glide freely. Percutaneous cutting of the tendon sheath has also been recommended (Lorthioir 1958).

Non-operative methods, especially suited for adult patients with a fairly short history, have also been recommended. These methods include immobilization (Flynn 1966, Sperling 1952) and X-ray therapy (Seedorff 1945), but the most common conservative method appears to be injection of small quantities of hydrocortisone into the tendon sheath (Bunnell 1964, Flynn 1966). Good results of this treatment have been reported by Howard et al. (1953), Schnohr et al. (1958), and by Zachariae & Zachariae (1954).

The object of the present study was to assess the effect of hydrocortisone injections into trigger fingers in adults, especially the long-term results.

The author has used the term "primary trigger finger" to include cases in which the phenomenon occurs in otherwise normal persons and often involves only the thumb, usually the right one. The other group, called "secondary trigger finger," comprises patients with rheumatoid arthritis, diabetes mellitus, or uncharacteristic rheumatism of the hands with joint stiffness and often Heberden nodules. It was characteristic of this latter group that the condition affects several fingers and that a number of patients also exhibit the carpal tunnel syndrome or de Quervain's syndrome.

MATERIAL

During the 5-year period 1962-1966, a total of 213 patients with trigger finger were treated in the Department of Hand Surgery, Orthopaedic Hospital, Copenhagen.

The adult patients were treated routinely by injecting 5-10 mg hydrocortisone into the proximal part of the tendon sheath. In some cases the injection was repeated, never more than twice, at 1-week intervals. Lacking an effect of this treatment, and in cases of recurrences, operation was advised.

All children were treated primarily by operation.

At follow-up in 1969 we contacted 168 patients, nearly all of whom attended a follow-up examination, although a few replied by letter or telephone.

Of these patients 112 were adults and 56 children. Out of the 112 adults, 95 were females and 17 males, with a pronounced age peak between 50 and 60.

106 adults had been treated by injections of hydrocortisone, 5-10 mg, into the tendon sheath as described above.

RESULTS

One week after the last injection of hydrocortisone, the symptoms as well as the objective trigger phenomenon had disappeared in 81 out of the 106 patients. In 10, however, the trigger phenomenon recurred

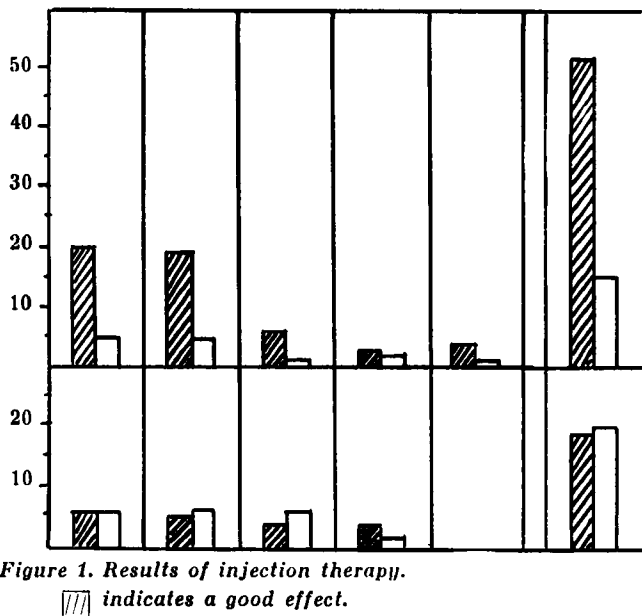
Duration of symptoms

<3 mo 3-6 mo 6-12 mo 1-5 yrs 5-10 yrs Total

Primary trigger fingers

Secondary trigger fingers

No. of pts.



after a symptom-free period of 1-4 months. The remaining 71 had not had any recurrences at follow-up 3-7 years later.

Among a total of 67 so-called primary trigger fingers, 52 gave a good response. Out of the 39 secondary trigger fingers, 19 obtained a lasting good effect. This is apparent from Figure 1 where, moreover, the duration of symptoms before treatment is plotted in relation to the therapeutic result. There is a faint tendency to better results after a short duration of symptoms and appreciably better results in the group of primary trigger fingers.

All 35 patients who failed to respond to the injections were subjected to operation. There has been only one recurrence in this group. Among the 6 adults who had primary operation, there have been no recurrences.

There were no cases in which rheumatoid arthritis had developed during the period between treatment and follow-up, so that the trigger finger might have been interpreted as the initial sign of this disease.

Among the 56 children included in the follow-up, 27 were girls and 29 boys. In 54 of these cases the thumb was affected, with almost equal frequency the right, left, and both thumbs. Fifty-two out of the 54 children arrived for operation before school age, the age peak

being at 2 years. Frequently the duration of the disease was somewhat uncertain, but most of the parents believed that the child had had the crooked finger from birth. The remaining 4 children were 9, 10, 10, and 15 years of age, and all were definitely believed to have had a crooked finger since birth. These older children reported that in general the finger did not give rise to pain.

There were no recurrences among the children.

CONCLUSION

From other publications it is known, and it is also apparent from the present investigation, that operation is an effective treatment of trigger finger which results in lasting cure in practically all cases.

On the other hand, good results have also been reported with various conservative measures, and in the present study the effect of injecting hydrocortisone into the tendon sheath was investigated. It was found to have given a lasting good effect in two-thirds of the cases. Among the primary trigger fingers, however, good results were obtained in more than three-quarters of the cases, among the secondary cases in less than one-half.

The duration of the disease did not appear to have much influence upon the results.

SUMMARY

A 5-year material of trigger fingers is presented with a follow-up period of 3-7 years. Of the patients included in the follow-up, 41 adults and 56 children had undergone operation, the majority of the adults after previous, unsuccessful treatment by hydrocortisone injections. Among the operated cases there was only one recurrence.

A total of 106 adults were primarily treated with injections of hydrocortisone into the tendon sheath. In 25 cases this treatment was ineffective, and in another 10 cases a recurrence appeared in a few months. The remaining 71 had not had recurrences at follow-up. In other words, the results of the injection therapy were inferior to those of surgery. This applies in particular to patients whose trigger fingers could be interpreted as a complication of rheumatoid arthritis, diabetes mellitus, or more uncharacteristic rheumatism of the hands. Within this group less than half the patients obtained good results. On the other hand, good results of the injection therapy were obtained in

about three-quarters of patients whose only complaint was a trigger finger.

The duration of symptoms before treatment did not appear to have much influence upon the results.

REFERENCES

- Bunnell, S. (1964) *Surgery of the hand*. 4th ed. Lippincott, Philadelphia.
- Fahey, J. J. & Bollinger, J. A. (1954) Trigger finger. *J. Bone Jt Surg.* **36-A**, 1200.
- Flynn, J. E. (1966) *Hand surgery*. Williams & Wilkins, Baltimore.
- Fogh-Andersen, P. (1947) Digitus saltans. *Nord. med.* **34**, 1151.
- Howard, L. D., Pratt, D. R. & Bunnell, S. (1953) The use of hydrocortisone. *J. Bone Jt Surg.* **35-A**, 994.
- Lorthioir, J. (1958) Surgical treatment of trigger finger. *J. Bone Jt Surg.* **40-A**, 793.
- Pulvertaft, R. G. (1966) *Clinical surgery, the hand*. Butterworths, London.
- Schnohr, E., Agner, O. & Hahn-Petersen, A. (1958) Treatment of bursitis, trigger finger, etc. *Acta chir. scand.* **115**, 319.
- Seedorf, K. S. (1945) Digitus saltans. *Ugeskr. Læg.* **107**, 622.
- Sperling, W. P. (1952) Snapping finger. *Acta radiol. (Stockh.)* **37**, 74.
- Zachariae, L. & Zachariae, F. (1954) Digitus saltans. *Ugeskr. Læg.* **116**, 1018.