


This article was downloaded by: [Anonymous Registration for mpptwo]

On: 8 November 2009

Access details: Access Details: [subscription number 780368323]

Publisher Informa Healthcare

Informa Ltd Registered in England and Wales Registered Number: 1072954 Registered office: Mortimer House, 37-41 Mortimer Street, London W1T 3JH, UK



Acta Orthopaedica

Publication details, including instructions for authors and subscription information:

<http://www.informaworld.com/smpp/title-content=t713400243>

Symphysiodesis with a new compression plate

Sven Olerud ^a; Gefl G. Walheim ^b

^a Department of Orthopaedic Surgery, University Hospital, Uppsala, Sweden ^b Department of Orthopaedic Surgery, Karolinska Hospital, Stockholm, Sweden

Online Publication Date: 01 June 1984

To cite this Article Olerud, Sven and Walheim, Gefl G.(1984)'Symphysiodesis with a new compression plate',Acta Orthopaedica,55:3,315 — 318

To link to this Article: DOI: 10.3109/17453678408992364

URL: <http://dx.doi.org/10.3109/17453678408992364>

PLEASE SCROLL DOWN FOR ARTICLE

Full terms and conditions of use: <http://www.informaworld.com/terms-and-conditions-of-access.pdf>

This article may be used for research, teaching and private study purposes. Any substantial or systematic reproduction, re-distribution, re-selling, loan or sub-licensing, systematic supply or distribution in any form to anyone is expressly forbidden.

The publisher does not give any warranty express or implied or make any representation that the contents will be complete or accurate or up to date. The accuracy of any instructions, formulae and drug doses should be independently verified with primary sources. The publisher shall not be liable for any loss, actions, claims, proceedings, demand or costs or damages whatsoever or howsoever caused arising directly or indirectly in connection with or arising out of the use of this material.

Symphysiodesis with a new compression plate

A specially designed compression plate has been used in symphysiodesis for chronic symphysiolysis with pelvic pain and discomfort suspected to be due to pelvic instability. Eight patients have been operated with this technique, and stable symphysiodesis was achieved in all. No signs of plate loosening were observed in any case.

**Sven Olerud &
Gert G. Walheim¹**

Department of Orthopaedic
Surgery, University Hospi-
tal, Uppsala, Sweden and

¹Department of Orthopaedic
Surgery, Karolinska Hospi-
tal, S-104 01 Stockholm,
Sweden

Fixation of the symphysis with a plate is usually done in traumatic injuries (Sharp 1973, Fink & Möseneder 1975, Lewis & Mayer 1977, Porsia & Cuomo 1977, Kamhin et al. 1980, Pennal & Massiah 1980, Kovalkovits et al. 1981, LeTournel & Judet 1981). Chronic painful symphysiolysis following parturition or trauma with pelvic discomfort and pain, which may be due to pelvic instability, can be managed by arthrodesis of the symphysis by plate fixation and bone grafting (Hagen 1974, Olerud & Grevsten 1974, Lie 1979).

We experienced difficulty with available plates in bending them correctly to fit the symphysis and in avoiding simultaneous deformation of the screw holes. A special plate was therefore designed for symphysiodesis with

satisfactory adaptation and stable fixation. The plate has proved to suit its purpose in eight patients.

Patients and methods

Patients

Seven women and one man had pain in the symphyseal and/or sacro-iliac region, which may have been due to pelvic instability (Table 1). In five women, movements in the symphysis were demonstrated by radiography according to Chamberlain (1930) with the patient standing alternately on the right and left leg. In all patients the symptoms had been of long duration with sick leave of 3 years in the mean.

In six of the female patients the symptoms were

Table 1. Patient material

Patient no.	Age (years)	Sex	Site of pain (Sy=symphysis S-i=sacroiliac joint)	Vertical motion of symphysis on radiographic examination* (mm)	Arthrodesis
1	23	F	Sy + S-i bilat.	4	Sy + S-i bilat.
2	30	F	Sy + S-i dx	0	Sy + S-i dx
3	31	F	Sy	10	Sy
4	32	M	Sy + S-i sin	0	Sy + S-i sin
5	33	F	Sy + S-i bilat.	5	Sy
6	38	F	Sy + S-i bilat.	0	Sy + S-i bilat.
7	38	F	S-i dx	4	Sy + S-i dx
8	42	F	Sy + S-i bilat.	5	Sy

* Measured according to Chamberlain (1930).




Figure 1. The internal fixation plate is made of stainless steel and shaped like a circular arc with a radius of 12 cm. It is available with four or six dynamic compression (DC) screw holes.

secondary to parturition. The male patient had had symptoms ever since a pelvic fracture 7 years prior to symphysiodesis. In one patient no apparent cause of the symptoms could be established.

In all eight patients, symphysiodesis was done by the technique described below. In five patients, arthrodesis of one or both sacro-iliac joints was done in an additional procedure.

Design of new plate for symphysiodesis

The plate* is made of stainless steel (AISI-316L). It is shaped like the arc of a circle with a radius of 12 cm and is available in two sizes, with a sector angle of 60° or 80°, and with four or alternatively six DC-type (Dynamic compression) screw holes (Figure 1). It is thus self-compressive.

Surgical technique

By a Pfannenstiel incision, the upper parts of both superior rami of the pubis are exposed. A wedge-shaped block of the upper half of the symphysis, about 15 mm in height, is removed by resecting 7–8 mm of the pubic bone on either side of the symphysis. A graft from the iliac crest, of similar shape to the removed wedge but slightly larger in size, is fitted into the space between the two pubic bones. Following this, the 4- or 6-hole screw plate is positioned over the symphysis and the graft. The graft is pressed into position from above by the plate and

kept firmly in place by the compression from both sides obtained by screwing home the plate. (Figures 2a, 2b). The central holes of the plate are placed so that two screws long enough to reach the inferior part of the pubic corpus can be inserted. One or two shorter screws are introduced lateral to each of the longer screws and thus into the superior pubic ramus. It is important that the two long screws do not penetrate the pubic arch by more than a few mm, otherwise damage to, for example, the vagina may be caused. For a more secure union, additional grafts can be placed into the subperiosteal pocket behind the upper part of the symphysis. These retropubic grafts should not be placed too inferiorly, as they might encroach on soft structures like, for example, the vagina. To ensure osseous union, a postoperative convalescent period of 3 months is required, the first 2 months without weightbearing and the 3rd with mobilization on crutches.

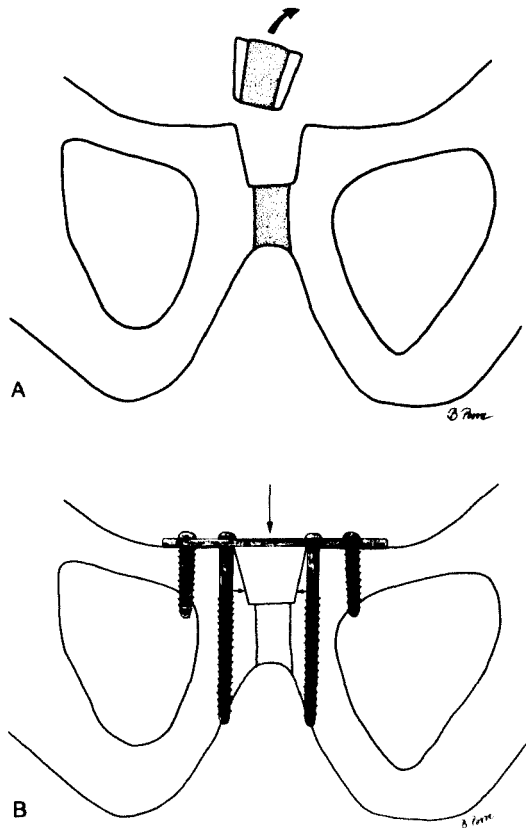


Figure 2a. Schematic illustration of the symphysis after resection of a wedge-shaped block from the superior part of the pubic corpus.
 b. A graft from the iliac crest placed into position and held under compression in both the supero-inferior and lateral directions (arrows).

* Commercially available from Straumann AB, Division Instrument Synthes, Box 919, S-181 09 Lidingö, Sweden.

Table 2. Results

Patient no.	Follow-up (months)	Site of residual pain (S-i=sacroiliac joint)	Time until callus formation (months)
1	11	S-i dx	5
2	41	—	4
3	12	—	2
4	28	—	9*
5	18	S-i bilat.	3.5
6	18	S-i bilat.	3
7	17	S-i sin	3
8	53	—	11**

* Time before first follow-up radiography.

** Radiography revealed at 3 months a slight loss of contours of the graft but no definite callus.

Results

During the observation period of 11–53 months (mean: 2 years) (Table 2), primary stable fixation tested with the Chamberlain technique was achieved in all eight patients. The seven patients with pain from the symphyseal region obtained complete or almost complete relief of this pain. Radiologic evidence of osseous union was seen within 3–6 months postoperatively. There was no loosening of the metal implant in any patient.

Discussion

Irrespective of the method of fixation of the symphysis, long-lasting stability cannot be expected as the load on the symphysis causes movements, which will lead to a loosening of an implant (Sharp 1973). Internal fixation of traumatic injuries is recommended by several authors, some of whom suggest a standard 4-hole plate, others plates bent on the flat (Lewis & Mayer 1977, LeTournel & Judet 1981). Sharp (1973) designed a strongly angled plate. Tile & Pennal (1980) recommend two plates, one placed superiorly and one anteriorly over the symphysis. Pennal & Massiah (1980) state that "contoured AO DCP plates adequately control the symphysis and can be supplemented as necessary with an external fixator and bone-grafting techniques". It seems probable that the efficacy of the internal fixation varies according to the severity of the pel-

vic injury, i.e. whether or not the posterior ligaments of the sacroiliac joints are damaged.

Pelvic discomfort and pain may be caused by an instability of the pelvis after parturition, but may also be observed following pelvic injury. Arthrodesis of the symphysis in cases of painful pelvic instability with a straight plate has been advocated by Lie (personal communication, 1979). Hagen (1974) and Olerud & Grevsten (1974) have reported plate fixation in combination with a solid bone graft after excision or resection, respectively, of the symphysis. The grafting procedure has been advocated, as plate fixation alone carries a risk of the screws working loose. The osseous union obtained by symphysiodesis resembles that developing in certain pathologic conditions: for example, ankylosing spondylitis, gynaecologic disorders and after prostatic surgery. The spontaneous rigidity in the symphyseal region has, to our knowledge, not caused any adverse reactions and this has led us to believe that a surgical symphysiodesis need not necessarily yield any untoward complications.

The primary aim in symphysiodesis is to create some form of bony bridge between the two pubic bones, which means that large demands are placed on the internal fixation device during the healing period. The plate used in this study, while requiring only limited exposure of the symphysis, allows satisfactory anatomical adaptation and stable internal fixation. Removal of the plate was not necessary in any of our patients and would seem to be required only if it should present a technical problem in connection with coitus.

References

- Chamberlain, W. E. (1930) The symphysis pubis in the roentgen examination of the sacro-iliac joint. *Am. J. Roentgenol.* **24**, 621–625.
- Fink, D. & Möseneder, H. (1975) Symphysen-sprengung mit primäre Verplattung. *Hefte Unfallheilk.* **124**, 292–293.
- Hagen, R. (1974) Pelvic girdle relaxation from an orthopaedic point of view. *Acta Orthop. Scand.* **45**, 550–563.
- Kamhin, M., Ganel, A., Salai, M. & Horoszowski, H. (1980) Rigid fixation in diastasis of symphysis pubis. *J. Trauma* **20**, 523–525.

- Kovalkovits, I., Tözsér, K., Miksi, G. & Frey, J. (1981) A symphyseolysis belső, stabil rögzítése. *Magyar Traumatológia* **24**, 23–27.
- LeTournel, E. & Judet, R. (1981) *Fractures of the acetabulum*. pp. 238, 250–251. Springer-Verlag, Berlin.
- Lewis, M. M. & Mayer, V. (1977) Pubic symphysis diastasis treated by open reduction and internal fixation. *Clin. Orthop.* **123**, 37–39.
- Lie, E. (1979) What can we offer patients with pelvic relaxation symptoms? Proceedings. *Acta Orthop. Scand.* **50**, 343.
- Olerud, S. & Grevsten, S. (1974) Chronic pubic symphyseolysis. A case report. *J. Bone Joint Surg.* **56-A**, 799–802.
- Pennal, G. F. & Massiah, K. A. (1980) Nonunion and delayed union of fractures of the pelvis. *Clin. Orthop. Rel. Res.* **151**, 124–129.
- Porsia, F. & Cuomo, R. (1977) Su un caso di disgiunzione della sinfisi pubica. Trattamento Chirurgico. *Minerva Med* **68**, 201–202.
- Sharp, I. K. (1973) Plate fixation of disrupted symphysis pubis. Preliminary report. *J. Bone Joint Surg.* **55-B**, 618–620.
- Tile, M. & Pennal, G. F. (1980) Pelvic disruption. Principles of management. *Clin. Orthop. Rel. Res.* **151**, 56–64.